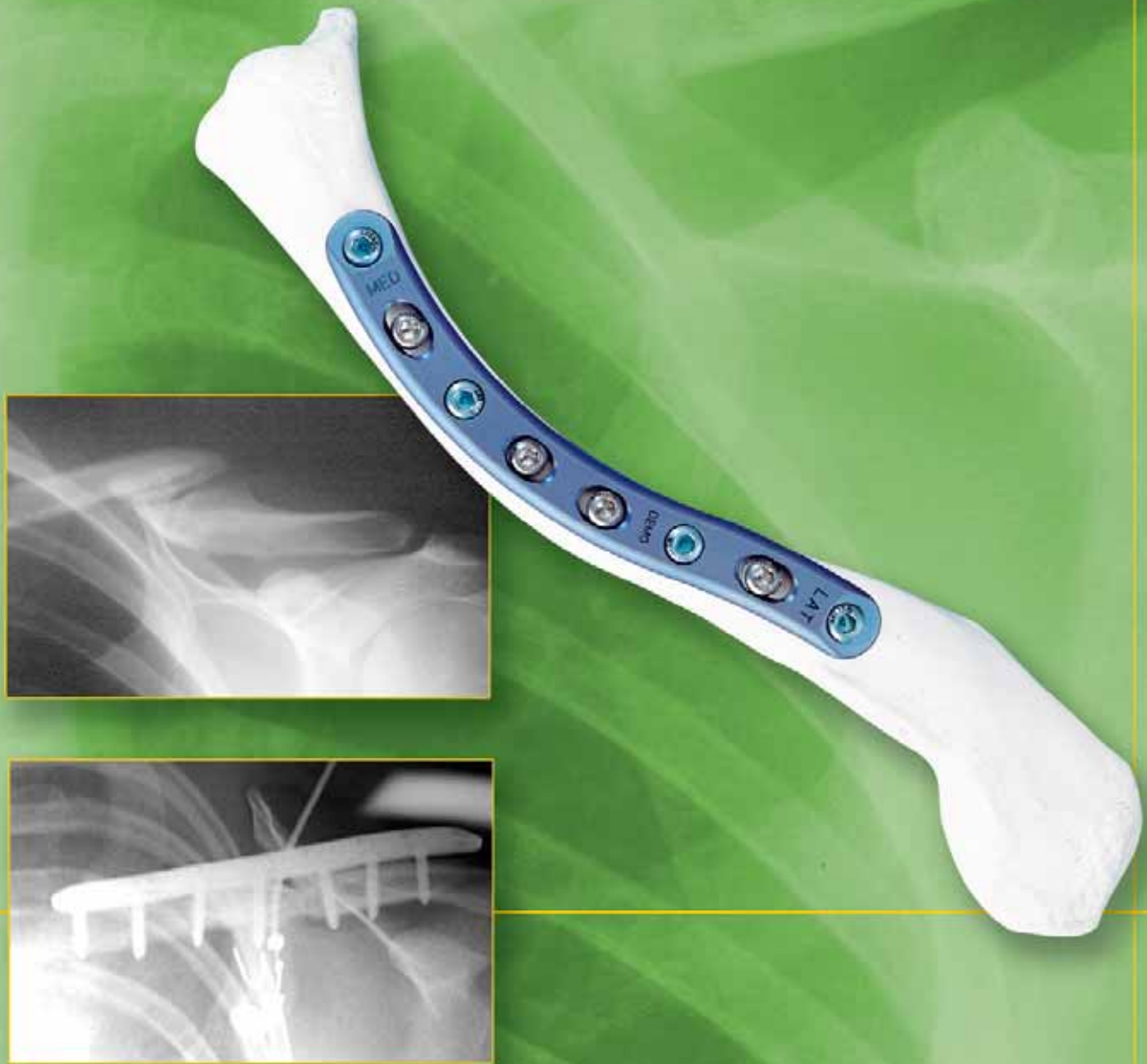

# A&U MED<sup>®</sup>



## LOCKING CLAVICLE PLATE SYSTEM

# LOCKING CLAVICLE PLATE SYSTEM

**Since 1988 Acumed has been designing solutions to the demanding situations facing orthopedic surgeons, hospitals and their patients. Our strategy has been to know the indication, design a solution to fit, and deliver quality products and instruments.**

Acumed's Locking Clavicle Plates are designed to provide excellent fixation for acute fractures, malunions, and non-unions of the clavicle.

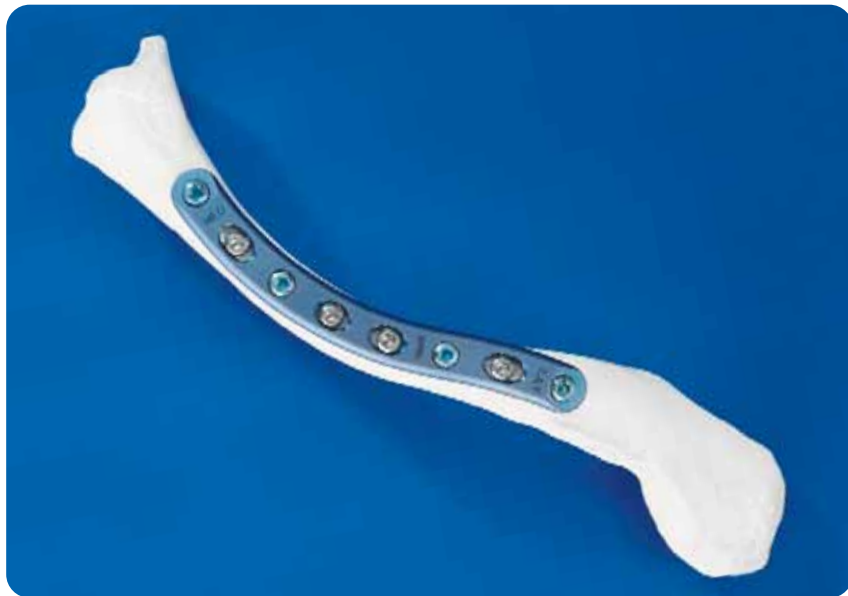While often treated conservatively, a portion of these fractures can benefit from a low profile, congruent, locking plate. Soft tissue irritation is minimized, and patient function improves while returning them to their normal activities sooner.

## Closed Treatment of Displaced Middle-Third Fractures of the Clavicle Gives Poor Results.<sup>1</sup>

The results of the 52 cases studied with an average follow-up of 38 months:

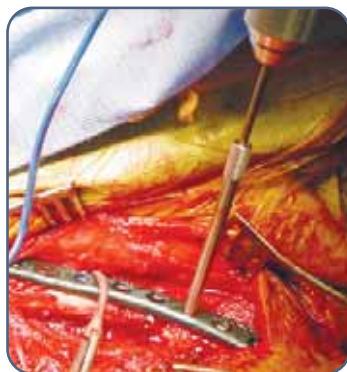- 15% nonunion rate
- 25% pain requiring NSAID's
- 36% difficulty lifting 20lb overhead
- 39% tenderness at fracture site
- 31% signs of nerve compression
- 31% were dissatisfied with the result

"We now recommend open reduction and internal fixation of severely displaced fractures of the middle third of the clavicle in adult patients"



With the Locking Clavicle Plates, Acumed has designed a comprehensive solution for repairing fractures located from the middle third to the distal third of the clavicle. Standard ORIF procedures for clavicle fractures including, pinning, reconstruction, and DC plating have historically provided less than desirable results.<sup>2</sup> Traditional hardware frequently causes soft tissue irritation and/or fails prior to union, requiring a second procedure.

Designed in conjunction with William Geissler, MD, the Locking Clavicle Plate offers a low profile solution for superior plating of the clavicle. Pre-contoured to match the natural S-shape of the clavicle, this titanium plate offers increased strength, with a rounded profile and a low-profile screw-plate interface. This design not only reduces OR time spent in contouring a plate but also minimizes soft-tissue irritation for the patient.

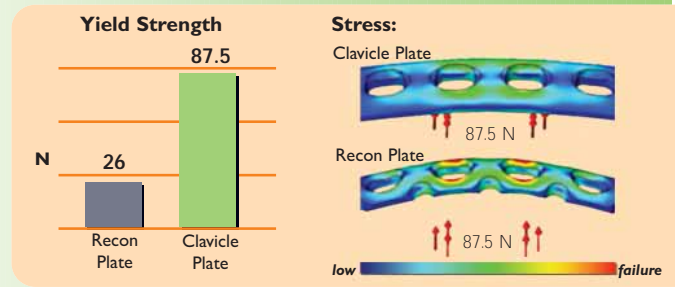


The Locking Clavicle Plates are included in a comprehensive system of implants and instrumentation specifically designed to treat clavicle injuries. Acumed's locking instrumentation provides a quick, straightforward means of inserting the locking screws with accurate precision each and every time.

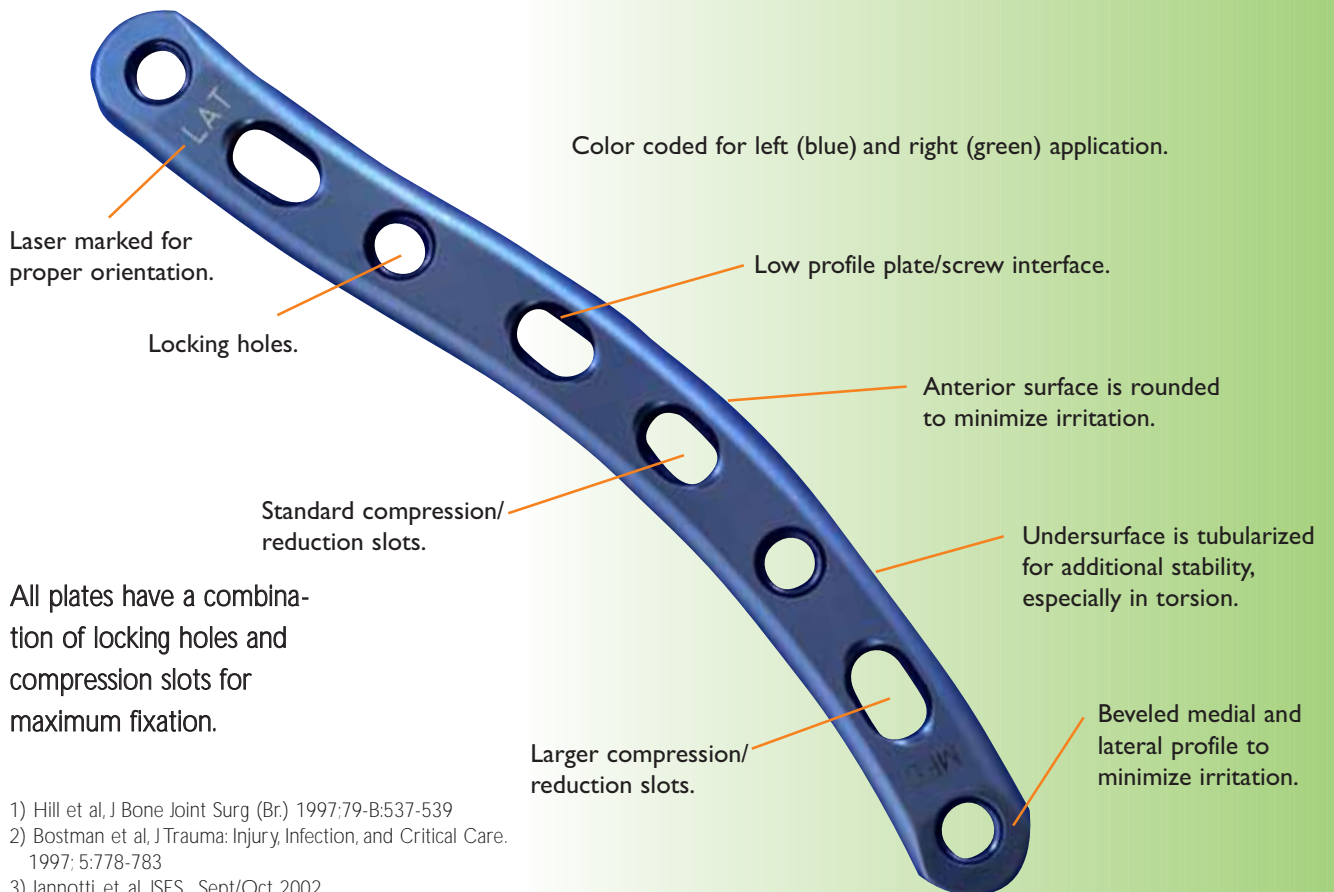
**Precontoured Plate Geometry** matches the anatomy of the patient with little or no bending. The Locking Clavicle Plate may also act as guide or template for restoring the patient's original anatomy when reconstructing a malunion, nonunion, or a highly comminuted fracture, unlike intramedullary rods/pins or straight plates.



**Superior Biomechanical Stability** is engineered into both the design of the plates and their orientation on the clavicle. Plating the superior aspect of the clavicle has been found to be biomechanically the most stable<sup>3</sup>. Acumed in house analysis showed that when subjected to equal force, a 3.5mm SS reconstruction plate broke in multiple locations while Acumed's clavicle plate suffered no permanent deformation<sup>4</sup>.



**Multiple Plate Options** are available to fit a wide variety of clavicle curvatures. For central one-third applications, there are five different lengths and curvatures in both left (blue) and right (green), and for distal/lateral fractures two specialized "J" plates are available.

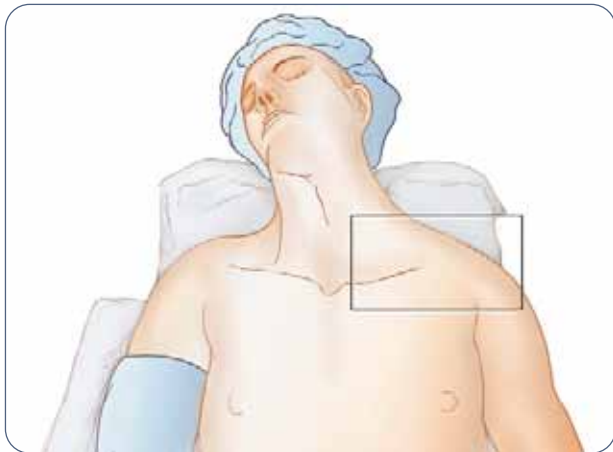


1) Hill et al, J Bone Joint Surg (Br.) 1997;79-B:537-539  
 2) Bostman et al, J Trauma: Injury, Infection, and Critical Care. 1997; 5:778-783  
 3) Iannotti, et, al, JSES, Sept/Oct 2002  
 4) Data on file at Acumed

# SURGICAL TECHNIQUE

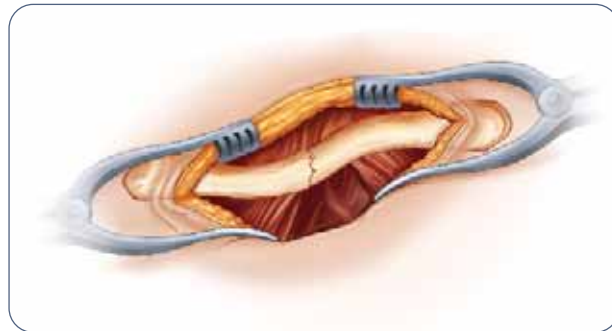
By William Geissler, M.D.

This section offers Acumed's suggested method for implanting the Locking Clavicle Plate. For specific questions not addressed here, please contact your local Acumed representative or Acumed at 888 627-9957.



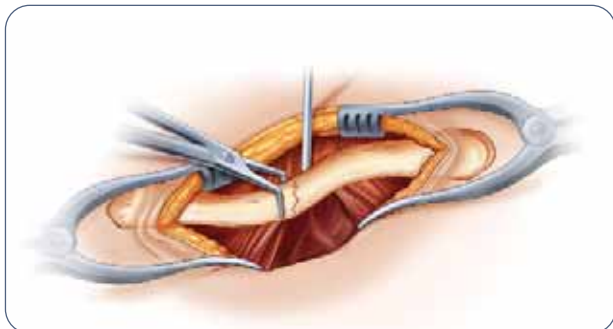
## Step 1: Patient Positioning

The patient is initially placed in the beach chair position. A bolster is placed between the shoulder blades to help facilitate reduction of the fracture during the case. The patient's involved upper extremity is prepped and draped in a sterile fashion allowing the arm to be manipulated to help further reduce the fracture if required.



## Step 2: Exposure

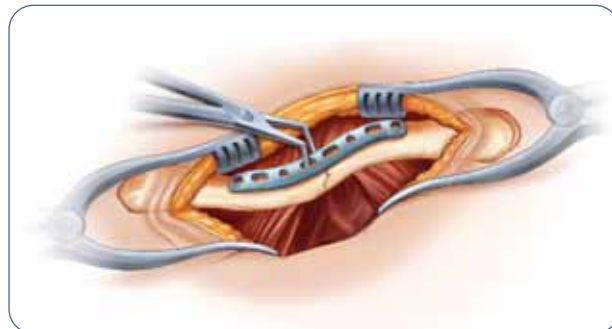
Approximately a six cm transverse (medial to lateral) incision is made over the palpable fracture of the clavicle, usually in the middle third. The medial fragment is usually proximal in relation to the distal fragment. The incision is usually placed midway between the proximal/distal migration of the proximal fragments. Dissection is carried down to the fascia and the skin flaps are elevated. The cutaneous nerves are protected. The musculature is then subperiosteally elevated off the bone fragments. It is important to keep soft tissue attachments to the butterfly fragments in an attempt to maintain vascularity. The fracture is reduced.



## Step 3: Plate Selection

The appropriately sized left or right clavicle plate is selected from the five different lengths and curvatures in the system. Usually the larger plates are ideal for most males, the medium plates for smaller males and most females, and the smallest plates for the smallest patients. The two middle slots may be placed over the fracture, ideally leaving two to three locking and/or non-locking holes both proximal and distal to the fracture fragments; however, the plate can be slid medially or laterally for the most ideal location. In cases of non-union or malunion, the curve of the plate can assist in anatomic reduction of the clavicle, reducing strain on the sternoclavicular and acromioclavicular joints.

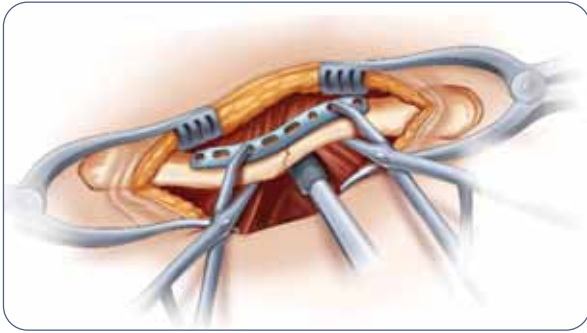
NOTE: Lag screw fixation across the major fracture fragment may be performed prior to placement of the plate. After the near cortex is drilled with the 3.5mm drill (MS-DC35), the 2.8/3.5mm drill sleeve (MS-DS2835) is inserted and the far cortex is drilled with a 2.8mm drill (MS-DC28).



## Step 4: Plate Placement

Once the plate's ideal positioning has been selected, it is provisionally stabilized to the clavicle with bone clamps (PL-CL04). The non-locking screws may be placed either unicortical or bicortical. If bicortical screws are used, it is important to not over-penetrate the distal cortex and potentially risk neurovascular injury. A curved retractor (PL-CL03) or other means of protection should be placed under the inferior surface of the clavicle to protect the neurovascular structures from over-penetration of the drill bit.

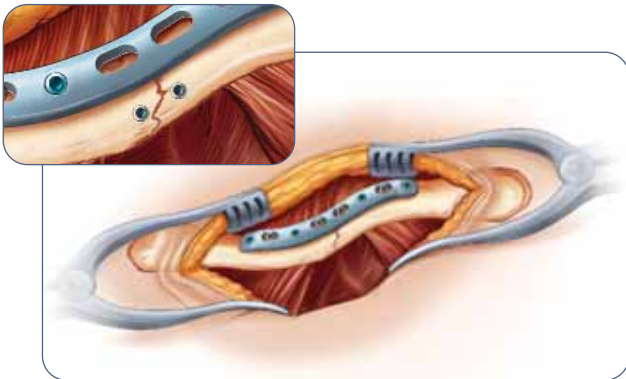
NOTE: The plate may be rotated 180° for a more anatomical fit on fractures that are more lateral than the central 1/3. A plate of the opposite dexterity may also be used if the patient's anatomy requires a different curvature than that provided with the correct-sided plate.



### Step 5: Non-Locking Screw Insertion

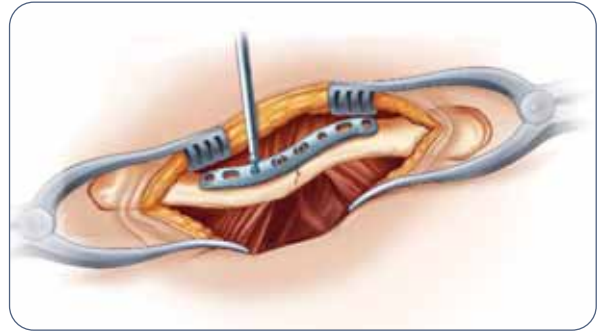
For early stability, the first two screws placed should be medial and lateral to the fracture site. Although 3.5mm screws (CO-3XX0) are recommended, optional 2.7mm (CO-27XX) and 4.0mm (CA-4XX0) screws are available upon request. Assemble the driver handle (MS-3200 or MS-1210) to the driver tip (HPC-0025 or HT-2502). Using the appropriate drill size (MS-DC28 or MS-DC5020) and the offset drill guide (PL-2095), drill, measure for depth (MS-9022) and place the screws into the slots with the assembled driver. Once the two screws are installed, the bone clamps (PL-CL04) holding the plate to the clavicle may be removed.

NOTE: The drill (MS-DC28 or MS-DC5020) will need to be replaced if it comes in contact with the retractor.



### Step 7: Final Plate and Screw Position

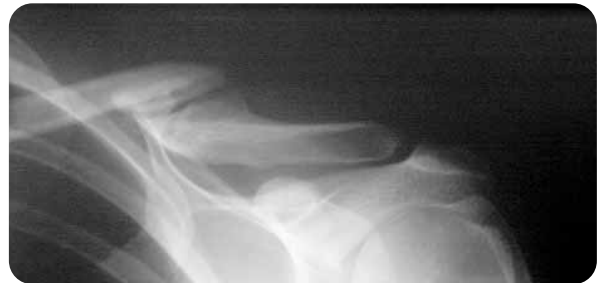An intraoperative radiograph is recommended to check the position of the screws and the final reduction of the fracture. If the surgeon feels the bone quality of the lateral fragment is poor, sutures may be passed from medial to lateral around the coracoid process and the plate to take stress off of the lateral fixation. The musculature is then re-approximated directly over the plate. The skin is then closed in layers with a subcuticular stitch for the remaining skin layer.



### Step 6: Locking Screw Insertion

Using the locking drill guide (MS-LDG35) and the 2.8mm drill (MS-DC28), place the 3.5mm locking screws (COL-3XX0) into the threaded holes so that there are at least three screws (if possible) on each side of the fracture.

NOTE: The bolster may be temporarily removed or the long driver tip (HT-2502) may be used if the patient's head is in the way during drilling and insertion of the screws. Once the screws are placed, the bolster may be replaced. Tapping (MS-LTT35 or MS-LTT27) is recommended for patients with dense bone. The drill guide (MS-LDG35) must be removed prior to tapping.



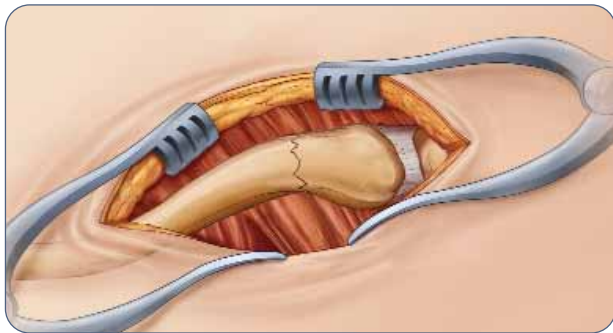
### Post-op Protocol

The patient is placed in an arm sling and starts pendulum range of motion exercises. Passive motion exercises are initiated from the first four weeks, active assisted from four to six weeks, and active strengthening is initiated at six weeks post operatively, once healing is seen radiographically.

# J-PLATE SURGICAL TECHNIQUE

By William Geissler, M.D.

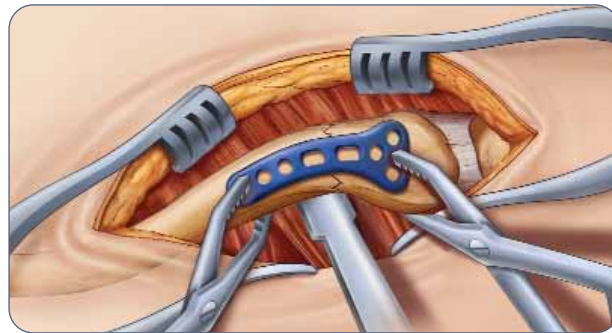
This section offers Acumed's suggested method for implanting the Congruent Clavicle Plate. For specific questions not addressed here, please contact your local Acumed representative or Acumed at 888 627-9957.



## Step 1: Exposure

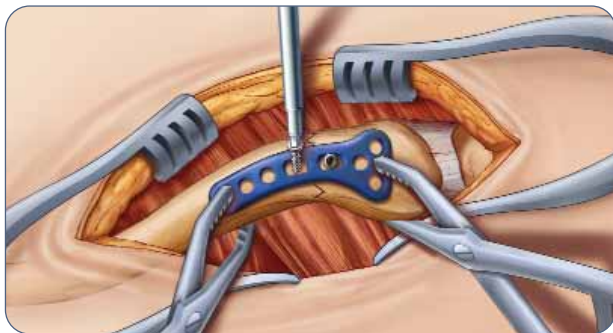
Approximately a six cm transverse (medial to lateral) incision is made over the palpable distal third fracture of the clavicle. The exposure is made using the same method described in the previous surgical technique. The fracture is reduced and the appropriate plate is selected.

Lag screw fixation across the major fracture fragment may be performed prior to placement of the plate. After the near cortex is drilled with the 3.5mm drill (MS-DC35), the 2.8/3.5mm drill sleeve (MS-DS2835) is inserted and the far cortex is drilled with a 2.8mm drill (MS-DC28).



## Step 2: Plate Placement

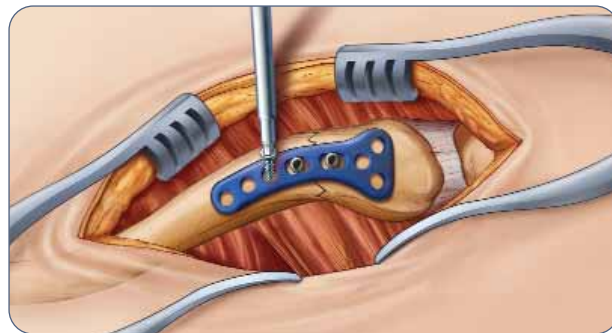
Once the plate's ideal positioning has been selected, it is provisionally stabilized to the clavicle with bone clamps (PL-CL04). The non-locking screws may be placed either unicortical or bicortical. If bicortical screws are used, it is important to not over-penetrate the distal cortex and potentially risk neurovascular injury. A curved retractor (PL-CL03) or other means of protection should be placed under the inferior surface of the clavicle to protect the neurovascular structures from over-penetration of the drill bit.



## Step 3: Non-Locking Screw Insertion

For early stability, the first two screws placed should be medial and lateral to the fracture site. Although 3.5mm screws (CO-3XX0) are recommended, optional 2.7mm (CO-27XX) and 4.0mm (CA-4XX0) screws are available upon request. Assemble the driver handle (MS-3200 or MS-1210) to the driver tip (HPC-0025 or HT-2502). Using the appropriate drill size (MS-DC28 or MS-DC5020) and the offset drill guide (PL-2095) drill, measure for depth (MS-9022) and place the screws into the slots with the assembled driver. Once the two screws are installed, the bone clamps (PL-CL04) holding the plate to the clavicle may be removed.

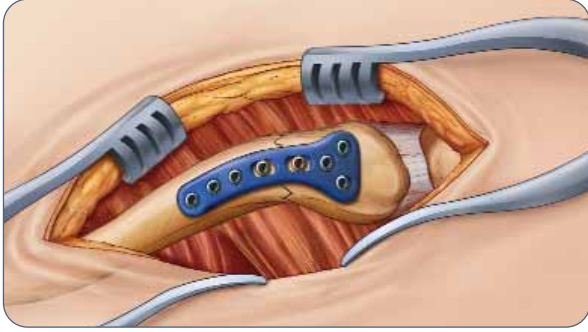
NOTE: The drill (MS-DC28 or MS-DC5020) will need to be replaced if it comes in contact with the retractor.



## Step 4: Locking Screw Insertion

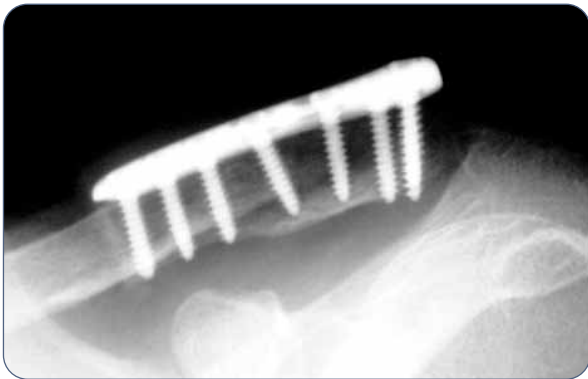
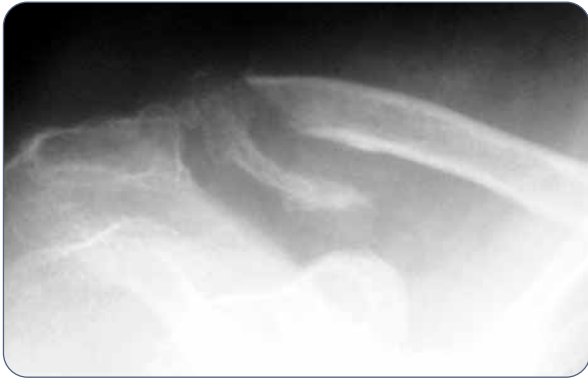Using the locking drill guide (MS-LDG35) and the 2.8mm drill (MS-DC28), place the 3.5mm locking screws (COL-3XX0) into the threaded holes so that there are at least three screws on each side of the fracture.

NOTE: The bolster may be temporarily removed or the long driver tip (HT-2502) may be used if the patient's head is in the way during drilling and insertion of the screws. Once the screws are placed, the bolster may be replaced. Tapping (MS-LTT35 or MS-LTT27) is recommended for patients with dense bone. The drill guide (MS-LDG35) must be removed prior to tapping.



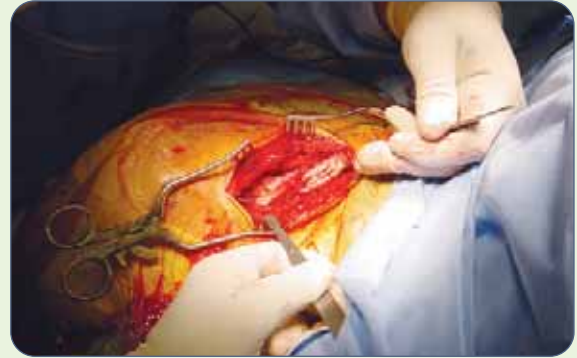
**Step 5: Final Plate and Screw Position**

An intraoperative radiograph is recommended to check the position of the screws and the final reduction of the fracture. If the surgeon feels the bone quality of the lateral fragment is poor, sutures may be passed from medial to lateral around the coracoid process and the plate to take stress off of the lateral fixation. The musculature is then re-approximated directly over the plate. The skin is then closed in layers with a subcuticular stitch for the remaining skin layer.

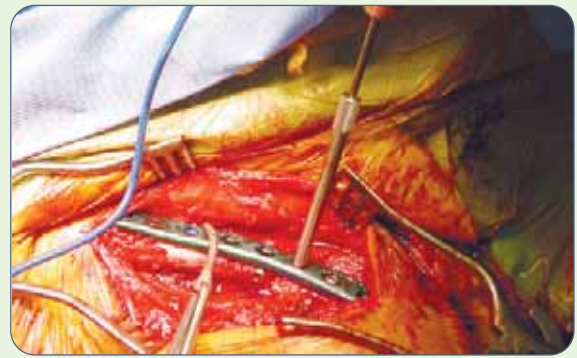


**Post-op Protocol**

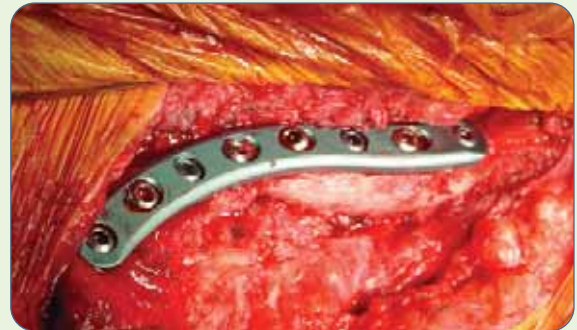The patient is placed in an arm sling and starts pendulum range of motion exercises. Passive motion exercises are initiated from the first four weeks, active assisted from four to six weeks, and active strengthening is initiated at six weeks post operatively, once healing is seen radiographically.



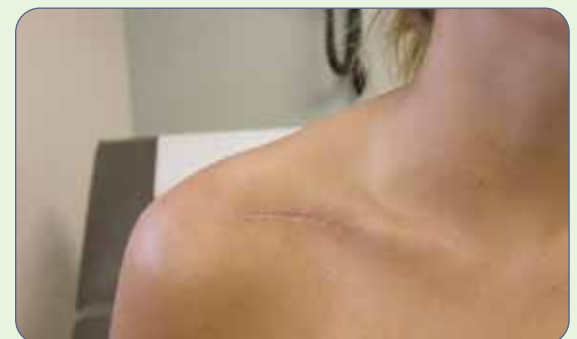Exposure



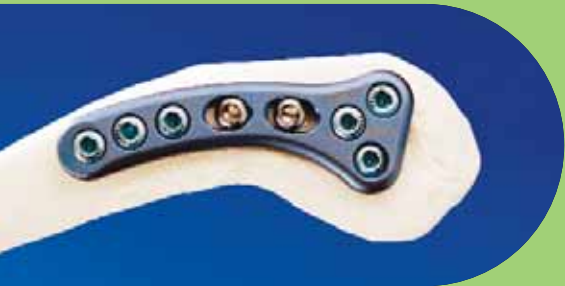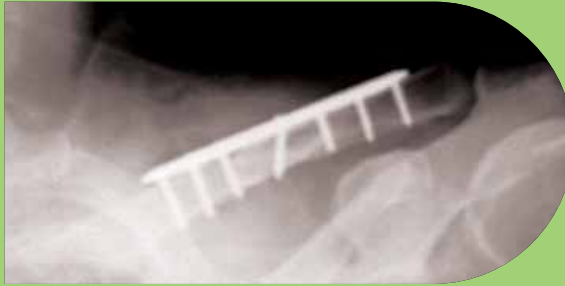Locking Drill Guide



Final Fixation



Minimal Scarring



**ACUMED®**  
5885 NW Cornelius Pass Road  
Hillsboro, OR 97124  
888 627-9957  
[www.acumed.net](http://www.acumed.net)

Distributed by:

Patent pending.  
CPS00-07-00  
Effective: 07/2005